

The American Journal of Sports Medicine

<http://ajs.sagepub.com/>

Glenohumeral Chondrolysis After Shoulder Arthroscopy : Case Reports and Review of the Literature

Damon H. Petty, Laith M. Jazrawi, Lance S. Estrada and James R. Andrews

Am J Sports Med 2004 32: 509

DOI: 10.1177/0363546503262176

The online version of this article can be found at:

<http://ajs.sagepub.com/content/32/2/509>

Published by:



<http://www.sagepublications.com>

On behalf of:



[American Orthopaedic Society for Sports Medicine](#)

Additional services and information for *The American Journal of Sports Medicine* can be found at:

Email Alerts: <http://ajs.sagepub.com/cgi/alerts>

Subscriptions: <http://ajs.sagepub.com/subscriptions>

Reprints: <http://www.sagepub.com/journalsReprints.nav>

Permissions: <http://www.sagepub.com/journalsPermissions.nav>

Glenohumeral Chondrolysis After Shoulder Arthroscopy

Case Reports and Review of the Literature

Damon H. Petty,^{*†} MD, Laith M. Jazrawi,[‡] MD, Lance S. Estrada,[§] MD, and James R. Andrews,^{||} MD

From [†]Petty Orthopaedics and Sports Medicine, Nashville, Tennessee, [‡]NYU Hospital for Joint Diseases, New York, New York, the [§]University of Alabama, Birmingham, Department of Orthopaedics, Birmingham, Alabama, and the ^{||}American Sports Medicine Institute, Birmingham, Alabama

Keywords: chondrolysis; articular cartilage; shoulder; arthroscopy

Glenohumeral chondrolysis is a rare and devastating complication of shoulder arthroscopy. No case reports of glenohumeral chondrolysis after routine shoulder arthroscopy appear in the literature. Three cases of rapid glenohumeral joint destruction following shoulder arthroscopy are described.

CASE 1

A 16-year-old male baseball and football player complained of pain in his right, dominant shoulder after 3 episodes of subluxation over the course of 2 years secondary to diving on the football and baseball fields. He was treated conservatively after each but failed to improve with 4 months of rehabilitation after the third subluxation. He underwent right shoulder arthroscopy in April 2001 at an outside institution for debridement of a posteroinferior labral tear. Figure 1 shows a preoperative radiograph of the affected shoulder. A radiofrequency ablator was used for this debridement. An extensive synovectomy and a coracoacromial ligament resection were also performed with the ablator followed by a modified subacromial decompression. His postoperative course was complicated by poor return of glenohumeral motion and mild to moderate pain with activities of daily living (ADLs). He was unable to return to sports.

His glenohumeral joint was injected 4 months after the procedure with steroid and marcadine. He reported good

immediate relief of pain following the injection with relief lasting for only 24 hours. Plain radiography was repeated at 5 months postoperative (Figure 2). It demonstrated significant glenohumeral space narrowing with early subchondral cyst formation in the glenoid. He presented to our clinic for the first time the following week. Range of motion (ROM) at that time was forward elevation to 180°, external rotation with elbow at the side to 60° and internal rotation to L4, and 1+ anterior laxity. Physical therapy was continued, focusing on maintaining glenohumeral ROM.

A rheumatologic evaluation was also recommended. It was subsequently normal. He returned again to our clinic 8 months after his shoulder arthroscopy. He described a slow progression of pain in his right shoulder since his last visit, now with substantial pain during ADLs. Plain radiographs demonstrated progression of the glenohumeral joint space narrowing (Figure 3). An MRI demonstrated thinning of the glenohumeral articular surfaces and subchondral cyst formation in the glenoid and humerus. A repeat arthroscopy was performed as a diagnostic maneuver to rule out infection and to obtain a synovial biopsy. Arthroscopic findings were as follows: the glenoid was devoid of articular cartilage, and the exposed subchondral bone appeared friable (Figure 4). The humeral head was covered with smooth hyaline cartilage, but marginal osteophytes were present. The synovium was red with numerous villous projections throughout. The labrum was degenerative circumferentially, also with villous fibrillations throughout (Figure 5). Operative cultures were negative for aerobes, anaerobes, acid-fast bacilli, and fungus. Biopsy of the synovium demonstrated numerous villous projections with polygonal to round stromal cells, some of which contained hemosiderin pigment. Rare multinucleated giant cells were present, with few chronic inflammatory cells and early pannus formation (Figure 6).

* Address correspondence to Damon H. Petty, Petty Orthopaedics and Sports Medicine, 1616 W. Main Street, Suite 300, Lebanon, TN 37087 (e-mail: damonhp@yahoo.com).

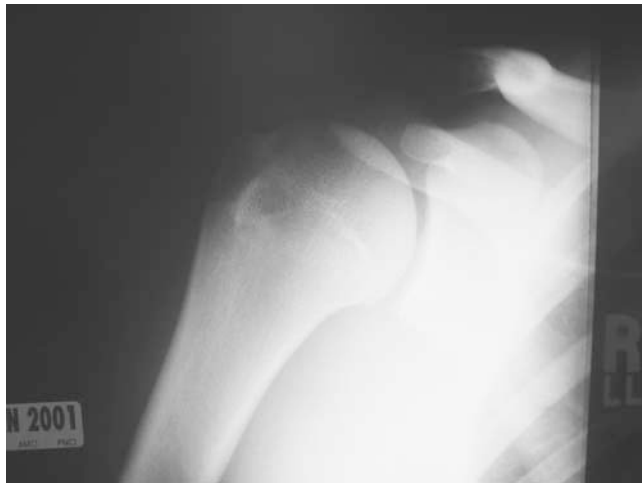


Figure 1. AP view of right shoulder (case 1), preoperative.

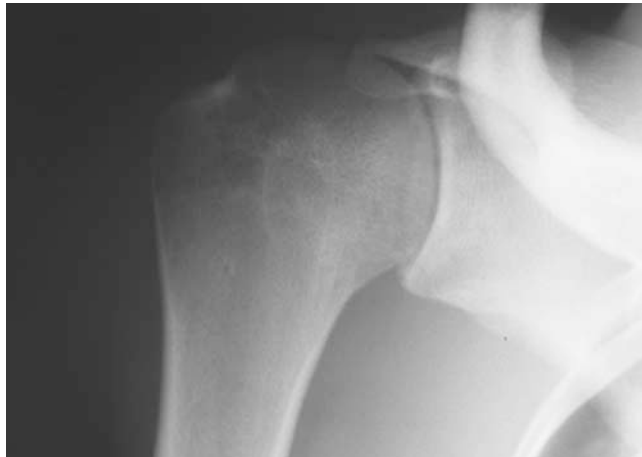

Figure 2. AP view of right shoulder (case 1) at 5 months after the index procedure shows marked narrowing of the glenohumeral joint.

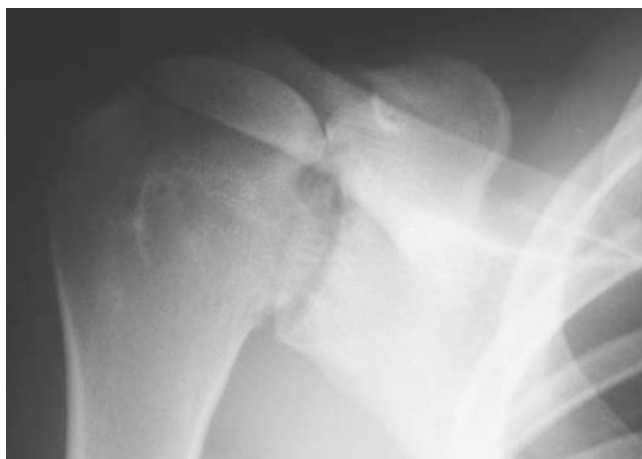

Figure 3. AP view of right shoulder (case 1) at 8 months after the index procedure shows progression of the glenohumeral narrowing.

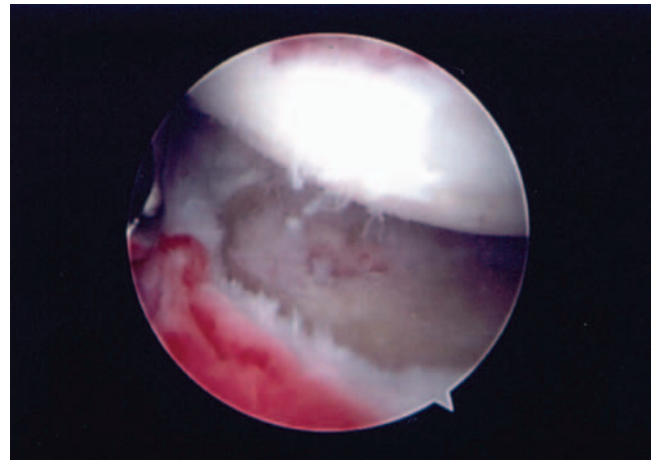


Figure 4. Arthroscopic photo (case 1) showing complete loss of glenoid hyaline cartilage with lesser changes in the humerus.

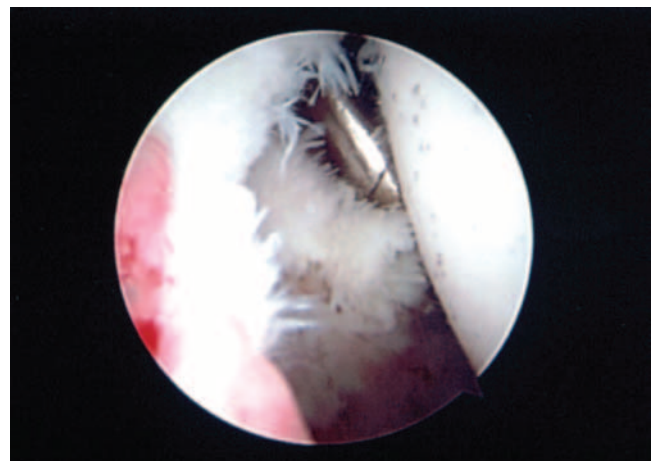


Figure 5. Arthroscopic photo (case 1) showing villous projections from the labrum and synovium.

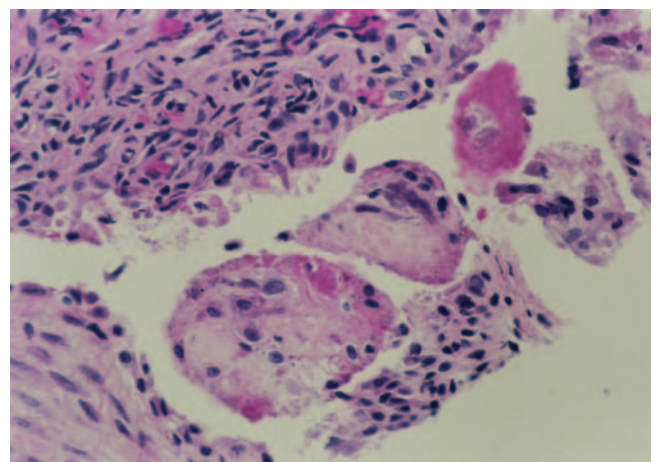


Figure 6. Histology specimen for case 1.

A presumptive diagnosis of glenohumeral chondrolysis with reactive synovitis was made. He reported moderate symptomatic relief in the early postoperative period, but by 1 month postoperative, his symptoms had worsened. He returned to our clinic 7 weeks after his diagnostic arthroscopy. Radiographs demonstrated further progression of his glenohumeral joint changes. Passive ROM at that time was forward elevation to 175°, external rotation to 60°, and internal rotation to L5. One year after his last arthroscopy, he continues to work to maintain ROM at the above values but has persistent and slightly progressive severe shoulder pain. He played his senior year of high school baseball as a designated hitter but was unable to throw.

CASE 2

A healthy, 18-year-old, right-hand-dominant female developed right shoulder pain after sliding head first into a base while playing softball. The history and physical exam suggested impingement syndrome and a possible rotator cuff tear and/or superior labral anterior posterior (SLAP) lesion. Radiographs revealed a type II acromion. MRI showed a small articular margin partial tear of the supraspinatus tendon. After failing a trial of conservative treatment including physical therapy and anti-inflammatory medications, a right shoulder arthroscopy with subacromial decompression and undersurface rotator cuff debridement was performed. The articular surface of both the humeral head and the glenoid had healthy-appearing cartilage at the time of arthroscopy. At the conclusion of the procedure, a pain pump was inserted with 0.5% bupivacaine and epinephrine.

The immediate postoperative course was unremarkable. No signs or symptoms of infection were noted. However, after 3 months of physical therapy, the patient still could not resume throwing because of limited external rotation and pain. She received a cortisone injection in her right shoulder that provided minimal relief. She sought a second opinion 5 months after the index procedure, and radiographs revealed marked narrowing of the right glenohumeral joint (Figures 7 and 8). MRI demonstrated narrowing of the glenohumeral joint with subchondral cystic changes in both the glenoid and humerus. A second shoulder arthroscopy was performed approximately 6 months after the initial procedure. Severe glenohumeral arthritis was observed. There was complete loss of the glenoid cartilage and significant loss of the humeral head cartilage. Extensive fraying of the anterior glenohumeral ligaments and of the labrum was noted. The rotator cuff appeared completely intact. The subacromial space was decompressed. Biopsy and culture of the synovium performed at the time of surgery yielded a negative gram stain, negative aerobic and anaerobic cultures, and negative acid-fast bacilli and fungal cultures. The stain for urate crystals was positive, however, and gross histologic examination revealed focal degenerative changes with microcalcifications with a foreign-body inflammatory reaction.

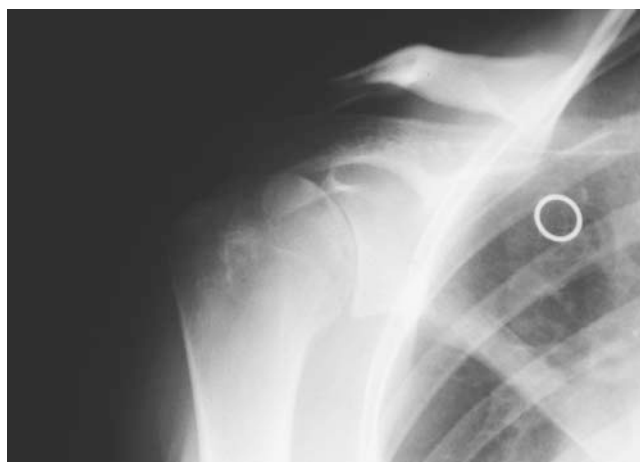

Figure 7. AP view of right shoulder (case 2) showing marked glenohumeral joint space narrowing 5 months after the index procedure.

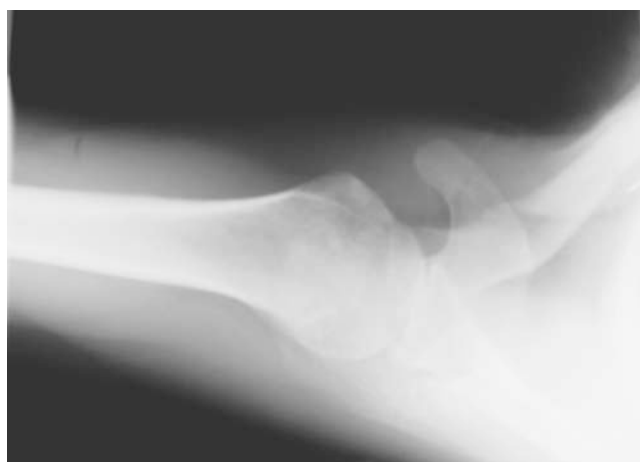


Figure 8. Axillary view of right shoulder (case 2) showing marked glenohumeral joint space narrowing 5 months after the index procedure.

The patient was referred for a third opinion 8 months after the index procedure, and a complete rheumatologic workup was initiated. Rheumatoid factor and antinuclear antibodies including smooth, anticontromere, nucleolar, speckled, and spindle were negative. Serum uric acid and complete blood counts with differential were within normal ranges. A presumptive diagnosis of glenohumeral chondrolysis was made. At follow-up 14 months after the index procedure, the patient still had right shoulder pain and a markedly impaired ROM but continues to be a designated hitter for her college softball team.

CASE 3

An 18-year-old competitive female high school softball player with a history of multidirectional right shoulder

instability and internal impingement presented to us 18 months after undergoing right shoulder arthroscopy, rotator cuff debridement (partial thickness tearing of <25%), and thermal capsular shrinkage using a monopolar device at an outside institution. Intraoperative findings demonstrated no chondral pathology. Postoperative rehabilitation was complicated by shoulder stiffness and persistent pain. Infection workup was negative. Physical exam findings were consistent with shoulder stiffness and pain at the extremes of shoulder ROM. Examination of the right shoulder demonstrated active forward elevation to only 100°. External rotation with the arm at the side was 35° (40° less than her unaffected extremity). External rotation with the shoulder at 90° abduction was 75° (40° less than her unaffected extremity). Internal rotation at 90° shoulder abduction was 25° (35° less than her unaffected extremity). Radiographs demonstrated glenohumeral joint space narrowing (Figures 9 and 10).

The patient complained that shoulder stiffness prevented her from throwing and batting. She was scheduled for

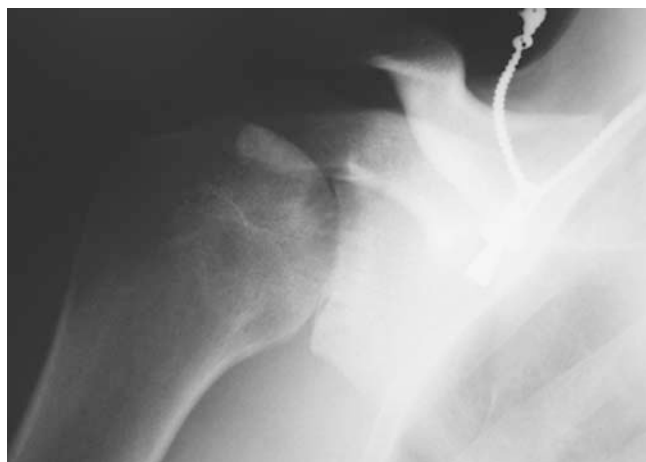

Figure 9. AP view of right shoulder (case 3) showing severe loss of glenohumeral joint space.

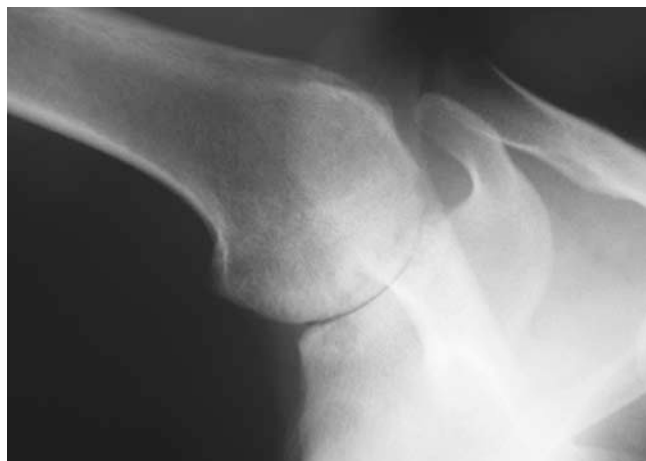

Figure 10. Axillary view (case 3) showing severe loss of glenohumeral joint space.

examination under anesthesia, manipulation, revision shoulder arthroscopy, lysis of adhesions, and synovial and bone biopsy. Examination under anesthesia and manipulation increased forward elevation to 180°, external rotation with the arm at the side to 60°, external rotation at 90° abduction to 90°, and internal rotation to 60°. Arthroscopy showed a degenerative and frayed labrum circumferentially (Figure 11). The capsule appeared thickened but intact. The glenoid was denuded of articular cartilage with evidence of patches of sclerotic bone. The humeral head showed areas of cartilage fibrillation and fissuring as well as small patches denuded of cartilage (Figure 12). Partial debridement of the labrum was completed followed by debridement of villous synovium in the capsular recesses.

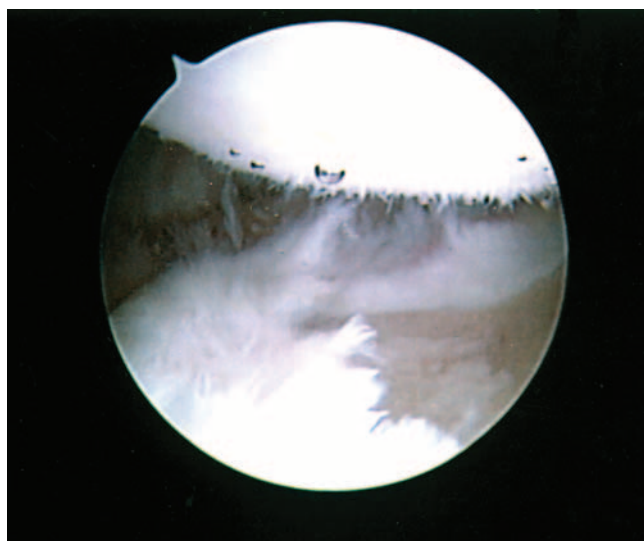


Figure 11. Arthroscopic photo (case 3) showing fraying and fibrillation of the labrum.

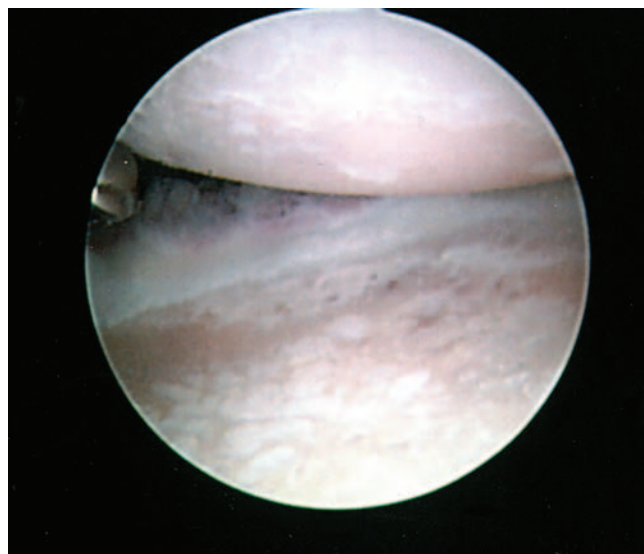


Figure 12. Arthroscopic photo (case 3) showing loss of all hyaline cartilage from the glenoid and the imaged portion of the humerus.

Synovial biopsy demonstrated dense fibrous connective tissue with areas of focal myxoid degeneration. The synovium was proliferative and had a ragged appearance. Increased numbers of chronic inflammatory cells were present within the underlying soft tissue.

Glenoid biopsy revealed normal bone and occasional areas of hyaline cartilage. Six weeks after this second procedure, her active elevation had increased to 150°, external rotation with her arm at her side was 45°, and external rotation at 90° of abduction was 80°. Her pain complaints were significantly improved with ADLs. Twelve months after her repeat arthroscopy, she had persistent shoulder pain but has maintained ROM. She is unable to throw effectively but continues to participate as a designated hitter.

DISCUSSION

The findings in these cases point to the diagnosis of glenohumeral chondrolysis. Little is known about the pathophysiology or natural history of this process. To our knowledge, glenohumeral chondrolysis has not been previously reported subsequent to shoulder arthroscopy. We were able to find only 2 case reports on chondrolysis specific to the shoulder in the world literature. In these reports, details of 3 cases of glenohumeral chondrolysis occurred after gentian violet was injected into the glenohumeral joint during rotator cuff repair to perform a "color test" to pinpoint the tear.^{16,20}

The gentian violet case reports point to the toxicity of gentian violet to chondrocytes, a fact that is corroborated by laboratory experience.²⁰ Other substances, such as chlorohexidine and methylmethacrylate, have been shown to cause chondrolysis in the knee and hip.^{12,22} There is, however, no indication that a chondrotoxic chemical was introduced into the glenohumeral joints of the patients reported here.

Thermal and/or radiofrequency energy can cause chondrocyte cell death.^{4,5,7,13,14} Two of the 3 cases reported here involved the use of radiofrequency energy within the glenohumeral joint. A significant increase in the temperature of arthroscopic fluid could lead to thermal tissue necrosis and is a potential etiology of diffuse chondrocyte death. The causal relationship here is unclear as Wong and Williams's retrospective review of 14,277 thermal procedures in the shoulder reported no known cases of acute glenohumeral chondrolysis.²⁵

Rapid chondrolysis of the lateral compartment of the knee has been reported in young athletes following lateral meniscectomy.² One of 4 reported cases involved the use of the holmium:yttrium-aluminum-garnet (HO:YAG) laser. Symptoms included pain and swelling with radiographic narrowing of the lateral knee compartment. A significant amount of chondral debris was present in these knees at repeat arthroscopy 6 months into the process. The etiology of this process is unknown.

Chondrolysis in the hip has been associated with penetration of pins or screws into the hip joint.¹⁹ The precise physiology of chondrolysis due to this mechanism has not been clearly defined, but it has been hypothesized that pro-

longed hardware penetration in the hip causes a mechanical irritation in conjunction with an immunologic process that subsequently erodes the hyaline cartilage.^{1,19} Transient pin penetration alone (in which a penetrating pin is removed at the time of the initial surgery) has a much lower, if any, association with chondrolysis.^{6,23,27} Also, chondrolysis can occur in untreated slipped capital femoral epiphysis (SCFE), pointing to the probability that the immunologic reaction is paramount in the process.^{15,23}

Idiopathic chondrolysis of the hip can also occur. The natural history of idiopathic hip chondrolysis is much more aggressive than chondrolysis secondary to SCFE. It demonstrates more rapid, progressive joint space narrowing.^{3,21} The cases of glenohumeral chondrolysis reported here behaved more like idiopathic hip chondrolysis than post-SCFE chondrolysis.

Chronic synovitis due to recurrent hemarthrosis can cause chondrolysis and joint destruction due to the release of hydrolytic enzymes within the joint by inflammatory cells within the synovium.¹⁷ Biopsy specimens from the 3 shoulders involved in this study showed chronic synovitis and inflammatory cells within the glenohumeral joint. This finding leads to the possibility that some event during the arthroscopy triggered an immune reaction and subsequent migration of inflammatory cells to the glenohumeral synovium, followed by the secretion of chondrolytic substances.

Visual evidence at arthroscopy also demonstrated that the erosive process included not only the articular surfaces of the joint but also the labrum, indicating that the destructive process was not restricted to hyaline cartilage.

Chondrolysis has been induced in vitro by exposure of hyaline cartilage to certain concentrations of fibronectin fragments (Fn-f).⁸⁻¹⁰ Fibronectin is a multidomain glycoprotein found on cell surfaces that acts to facilitate binding of cellular materials with the extracellular matrix. It serves many systems in different forms, including the migration of cells during wound healing, phagocytosis, and the clotting pathways. Its plasma form is highly reactive with the glycosaminoglycan heparin. Fibronectin also binds well to other glycosaminoglycans, including those crucial to the form and function of hyaline cartilage—chondroitin sulfate and hyaluronic acid.

In hyaline cartilage, fibronectin is manufactured in the chondrocytes and resides in the extracellular matrix, where it is involved in maintenance of proteoglycan concentration. When fragmented by proteases, the resultant Fn-f can interact with the chondrocytes to induce increased production of metalloproteinases and other proteinases (stromelysin-1), resulting in reduced proteoglycan synthesis and increased proteoglycan breakdown.^{8,9,26} Pathways for this process include reactive oxygen species and various cytokines, the most prominent of which are TNF-alpha, IL-1 alpha and beta, and IL-6.¹⁸

The catabolic effects of Fn-f exposure can be reduced in vivo by blocking various elements of the pathway, including neutralizing antibodies to catabolic cytokines (TNF-alpha, IL-1 alpha and beta, IL-6), or the presence of high-molecular-weight hyaluronic acid to block Fn-f interaction with chondrocytes and the presence of substances

that neutralize reactive oxygen species such as N-acetylcysteine.^{8,10,11,24}

These cases all occurred in young throwing athletes, resulting in significant pain and functional deficits. We elected to perform minimal intervention in these cases due to the advanced yet progressive status of their disease at presentation. A repeat arthroscopy with limited debridement of the labrum and synovium was performed for palliative and diagnostic purposes. Physical therapy was emphasized to maintain ROM and strength. Nonsteroidal anti-inflammatory drugs were used judiciously. All were allowed to return to their sport as tolerated.

For chondrolysis of the lateral compartment of the knee following arthroscopic lateral meniscectomy, Charrois et al have recommended early repeat arthroscopy, steroid injection, and a period of nonweightbearing.² A similar protocol could be applied to the treatment of rapid glenohumeral chondrolysis if diagnosed early, before substantial joint space narrowing has occurred. Any synovial hypertrophy should be addressed at the time of arthroscopy. Based on the research of Homandberg et al cited above,¹¹ the additional injection of a high-molecular-weight hyaluronic acid analog could also be beneficial in the early stages of the disease.

Early recognition of glenohumeral chondrolysis requires 6- and 12-week evaluation following shoulder arthroscopy. Pain out of proportion to expectations during motion exercises or significant difficulty regaining motion should prompt radiographic evaluation of the operative shoulder. Although arthroscopic stabilization procedures mandate postoperative motion restriction, excessive pain or crepitus during motion within the prescribed range should alert the physician to the possibility of chondrolysis.

Treatment options during the subacute phase would include repeat arthroscopy with synovectomy, steroid injection, and/or injection of a high-molecular-weight hyaluronic acid visco supplement.

Treatment options in the early chronic phase of the process are limited to conservative and palliative treatments. The diffuse nature of the cartilage degeneration and poor quality of glenoid bone stock seen in these reported patients made cartilage restoring procedures such as microfracture, osteochondral autografting, or autologous chondrocyte implantation (Genzyme) unlikely to succeed. Anecdotal accounts of meniscal allograft interpositional glenoid arthroplasty for this condition have yielded mixed results.

CONCLUSIONS

Glenohumeral chondrolysis is a rare and disturbing complication of routine shoulder arthroscopy. The disease pathophysiology is currently not understood. Although thermal energy is suspected to play a role, it cannot explain known cases of glenohumeral chondrolysis in which no thermal energy was involved. We, however, do recommend avoiding the use of ablative thermal energy in the glenohumeral joint of young patients. Other relevant causal factors may include patient age, the use of bioab-

sorbable material within the joint, mechanical trauma to the joint surface from arthroscopic instruments, or chemical trauma to the hyaline cartilage. No specific treatment regimen for glenohumeral chondrolysis has been described in the literature.

We do not know the natural history of this process. It appears, however, that the prognosis for these shoulders is grim. Prosthetic glenohumeral arthroplasty is relatively contraindicated due to the young age and functional demands of these patients. If it becomes clear that a conservative approach is unsuccessful in managing their symptoms, these patients may be reevaluated for consideration of more aggressive interventions.

REFERENCES

- Aprin H, Goodman S, Kahn LB. Cartilage necrosis due to pin penetration: experimental studies in rabbits. *J Pediatr Orthop.* 1991;11(5):623-630.
- Charrois O, Ayrat X, Beaufile P. Rapid chondrolysis after arthroscopic external meniscectomy: apropos of 4 cases. *Rev Chir Orthop Reparatrice Appar Mot.* 1998;84(1):88-92.
- Del Cruz G, Fernandez PL, Gonzalez MP, et al. Idiopathic chondrolysis of the hip: long-term evolution. *J Pediatr Orthop.* 1999;19(4):449-454.
- Edwards RB, Lu Y, Nho S, et al. Thermal chondroplasty of chondromalacic human cartilage: an ex vivo comparison of bipolar and monopolar radiofrequency devices. *Am J Sports Med.* 2002;30(1):90-97.
- Edwards RB, Lu Y, Rodriguez E, et al. Thermometric determination of cartilage matrix temperatures during thermal chondroplasty: comparison of bipolar and monopolar radiofrequency devices. *Arthroscopy.* 2002;18(4):339-346.
- Emery RJ, Todd RC, Dunn DM. Prophylactic pinning in slipped upper femoral epiphysis: prevention of complications. *J Bone Joint Surg Br.* 1990;72(2):217-219.
- Hogan CJ, Diduch DR. Progressive articular cartilage loss following radiofrequency treatment of a partial-thickness lesion. *Arthroscopy.* 2001;17(6):E24.
- Homandberg GA, Hui F, Wen C. Fibronectin fragment mediated cartilage chondrolysis I: suppression by anti-oxidants. *Biochim Biophys Acta.* 1996;1317(2):134-142.
- Homandberg GA, Hui F, Wen C. Fibronectin fragment mediated cartilage chondrolysis II: reparative effects of anti-oxidants. *Biochim Biophys Acta.* 1996;1317(2):143-148.
- Homandberg GA, Hui F, Wen C, et al. Fibronectin-fragment-induced cartilage chondrolysis is associated with release of catabolic cytokines. *Biochem J.* 1997;321(pt 3):751-757.
- Homandberg GA, Hui F, Wen C, et al. Hyaluronic acid suppresses fibronectin fragment mediated cartilage chondrolysis: I—in vitro. *Osteoarthritis Cartilage.* 1997;5(5):309-319.
- Leclair A, Gangi A, Lacaze F. Rapid chondrolysis after an intra-articular leak of bone cement in treatment of a benign acetabular subchondral cyst: an unusual complication of percutaneous injection of acrylic cement. *Skeletal Radiol.* 2000;29(5):275-278.
- Lu Y, Edwards RB, Cole BJ, et al. Thermal chondroplasty with radiofrequency energy: an in vitro comparison of bipolar and monopolar radiofrequency devices. *Am J Sports Med.* 2001;29(1):42-49.
- Lu Y, Edwards RB, Kalscheur VL, et al. Effect of bipolar radiofrequency energy on human articular cartilage: comparison of confocal laser microscopy and light microscopy. *Arthroscopy.* 2001;17(2):117-123.
- Lubicky JP. Chondrolysis and avascular necrosis: complications of slipped capital femoral epiphysis. *J Pediatr Orthop B.* 1996;5(3):162-167.
- Nakagawa Y, Ueo T, Miki T, et al. Glenohumeral osteoarthritis following a "color test" during rotator cuff repair: a case report and review

- of the literature. *Bulletin: Hospital for Joint Diseases*. 1998;57(4):216-218.
17. Rodríguez-Merchan EC. The destructive capabilities of the synovium in the haemophilic joint. *Haemophilia*. 1998;4(4):506-510.
 18. Sakai T, Kambe F, Mitsuyama H, et al. Tumor necrosis factor alpha induces expression of genes for matrix degradation in human chondrocyte-like HCS-2/8 cells through activation of NF-kappaB: abrogation of the tumor necrosis factor alpha effect by proteasome inhibitors. *J Bone Miner Res*. 2001;16(7):1272-1280.
 19. Sternlicht AL, Erlich MG, Armstrong AL, et al. Role of pin protrusion in the etiology of chondrolysis: a surgical model with radiographic, histologic, and biomechanical analysis. *J Pediatr Orthop*. 1992;12(4):428-433.
 20. Tamal K, Higashi A, Cho S, et al. Chondrolysis of the shoulder following a "color test"-assisted rotator cuff repair: a report of 2 cases. *Acta Orthop Scand*. 1997;68(4):401-402.
 21. Tudisco C, Caterini R, Farsetti P. Chondrolysis of the hip complicating slipped capital femoral epiphysis: long-term follow-up of nine patients. *J Pediatr Orthop B*. 1999;8(2):107-111.
 22. Van Huyssteen AL, Bracey DJ. Chlorhexidine and chondrolysis in the knee. *J Bone Joint Surg Br*. 1999;81(6):995-996.
 23. Vrettos BC, Hoffman EB. Chondrolysis in slipped upper femoral epiphysis: long-term study of the aetiology and natural history. *J Bone Joint Surg Br*. 1993;75(6):956-961.
 24. Williams JM, Plaza V, Hui F, et al. Hyaluronic acid suppresses fibronectin fragment mediated cartilage chondrolysis: II—in vivo. *Osteoarthritis Cartilage*. 1997;5(4):235-240.
 25. Wong KL, Williams GR. Complications of thermal capsulorrhaphy of the shoulder. *J Bone Joint Surg Am*. 2001;83(A)(suppl 2, pt 2):151-155.
 26. Xie DL, Hui F, Meyers R, et al. Cartilage chondrolysis by fibronectin fragments is associated with release of several proteinases: stromelysin plays a major role in chondrolysis. *Arch Biochem Biophys*. 1994;311(2):205-212.
 27. Zionts LE, Simonian PT, Harvey JP. Transient penetration of the hip joint during in situ cannulated-screw fixation of slipped capital femoral epiphysis. *J Bone Joint Surg Am*. 1991;73(7):1054-1060.